

PRESENTING CLINICAL SIGNS

History: Anxious, lethargic, changing coat color. Mass on right dorsal hip.

DATE

12/6/21

ECHOCARDIOGRAPHIC FINDINGS

2D, M-mode, and Doppler study.

PERFORMED BY:

Dr. Brian Barnes

INTERPRETED BY

Keith Blass, DVM,
MS, DACVIM
(Cardiology)

Left atrial size is normal. The mitral valve leaflets are mildly thickened, and a mild jet of eccentric mitral regurgitation is present. Left ventricular dimensions are normal. Left ventricular systolic function is normal. The aorta and aortic are normal. Right atrial and right ventricular dimensions are normal. The tricuspid valve appears normal, though trace tricuspid regurgitation is present. The pulmonary artery and pulmonic valve appear normal, though trace pulmonic insufficiency is present. No pericardial effusion or cardiac masses are seen.

ECG during echo: Sinus arrhythmia

PATIENT

Lily Welp

LA - 41.4 mm
LVIDd - 42.7 mm
LVIDs - 31.4 mm
FS - 26.4%
RA - 17.1 mm
LVOT - 1.54 m/s
RVOT - 0.88 m/s

SPECIES

Canine

ASSESSMENT/RECOMMENDATIONS

Degenerative mitral valve disease

BREED

Golden Retriever

This examination demonstrates mild regurgitation of blood across Lily's mitral valve resulting from degenerative valve disease. The hemodynamic effects of the regurgitation also appear to be mild, as Lily does not have secondary dilation of either of her left heart chambers. As such, Lily's mitral valve disease appears to be well-compensated, and her current risk for the development of clinical signs secondary to it appears to be low.

SEX

No evidence of cardiac neoplasia is appreciated in the image set.

FS

No therapy is recommended based on this exam.

AGE

10 y

A recheck echocardiogram is recommended in 6 months to monitor for disease progression.

WEIGHT

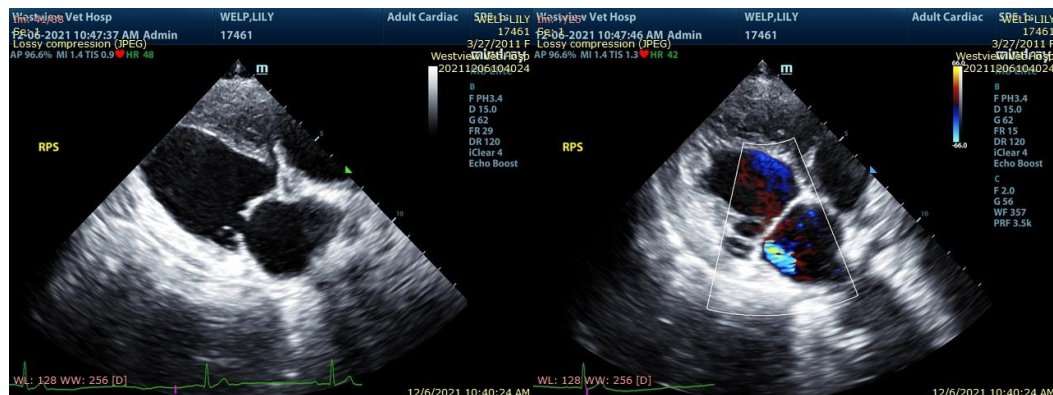
31.95 kg

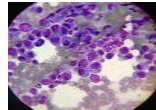
HOSPITAL NAME

Westview VH

REFERRING VET

Dr. Barnes





DATE

12/6/21

The information and recommendations provided are based on the images presented by the referring veterinarian. No evaluation can be communicated regarding pathology that was not visible in the image/video clips provided.

PERFORMED BY:

Thank you for this referral. If the clinical or image interpretation does not parallel your findings or if I can be of any further assistance please contact me.

Dr. Brian Barnes

INTERPRETED BY

Keith Blass, DVM, MS, DACVIM (Cardiology)
KeithBlass@gmail.com
631-804-5754

Keith Blass, DVM,
MS, DACVIM
(Cardiology)

PATIENT

Lily Welp

SPECIES

Canine

BREED

Golden Retriever

SEX

FS

AGE

10 y

WEIGHT

31.95 kg

HOSPITAL NAME

Westview VH

REFERRING VET

Dr. Barnes